**Original Paper****Modified form of the Elnady Technique for tissues preservation**Anwar El- Shafey¹, Yasmeen Magdy¹, Ahmed Hamad², Osama Ahmed¹¹Department of Food Anatomy and Embryology, Faculty of Veterinary Medicine, Benha University, Egypt²Department of Hygiene and Control, Faculty of Veterinary Medicine, Benha University, Egypt**ARTICLE INFO****Keywords**

Modified Elnady technique
plastination
Heparin
preservation

Received 17/09/2021**Accepted** 12/10/2021**Available On-Line**

01/01/2022

ABSTRACT

The continuous exposure of students to formalin leads to severe adverse effects on their health, in addition to the annual increase in the number of students with the stability of the financial resources of the college, made the need to develop new ways through which to overcome those challenges, which is a modified form of the Elnady Technique for tissues preservation, where the Heparin was injected into the common carotid artery to complete the bleeding process, the technique has proceeded at room temperature and the chemicals used are easily obtainable and cheap including formalin, acetone, glycerin and cornstarch for fixation, dehydration, impregnation and curing respectively. The produced specimens are naturalistic, long-lasting and have no offensive odor. They can be used instead of using the killed animals for dissection in teaching veterinary anatomy, embryology, pathology, ichthyology, parasitology and forensic medicine. They may play a great role in enhancing clinical and surgical skills training.

1. INTRODUCTION

Plastination is the process of maintaining tissue in a "life-like" state by supplanting body liquids (fat and water) with manufactured materials such as silicone, epoxy, and polyester. That's designed by Gunther von Hagens in 1977 (von Hagens, 1979). Fixation, Dehydration, Forced Impregnation in a vacuum, and curing (hardening) are the four consecutive stages in the conventional plastination process (Bickley, 1984).

For human cadaver mummification, ancient Egyptian embalmers utilized natron, and centuries later, various embalming solutions such as formalin were devised. Formalin fixation is widely recognized (Brenner, 2014). It can be carried out in a variety of techniques, comprising injection, infiltration, immersion, or diffusion (Ostrom, 1987).

Fixation can be carried out by virtually all common fixatives (Pashaei, 2010). Acetone is used primarily for dehydration although it also acts as an intermediate solvent during impregnation (Srisuwatanasagul et al., 2010).

The most essential step in plastination is forced impregnation, in which a vacuum pushes the acetone out and the polymer into the specimen. Hardening or curing is the final step were exposing the impregnated specimen either to a gaseous hardener (silicone), or by Ultraviolet A-light and heat and become hardened (Pashaei, 2010).

Plastination can be used to preserve surgically removed tissues and pathological specimens for education and research (Ravi and Bhatt, 2011). Endoscopic skills can be taught using a plastinated animal's tracheobronchial tree and gastrointestinal system (Elnady et al., 2015). Mummies

that have been exhumed, rare animals and historic materials can all be plastinated and displayed at museums (Kamath et al., 2013). In the present study, we describe a modified form of Elnady Technique for tissues preservation. The produced samples by this method are life-like, long-lasting, more flexible with being odorless, non-toxic and non-infectious those are ideal for teaching gross anatomy, relations, neuroanatomy and also maintain the histology of the tissues.

2. MATERIAL AND METHODS**2.1. Animals and organs:**

This research was carried out at the Department of Anatomy and Embryology, Faculty of Veterinary Medicine, Benha University, Egypt. According to the InterNICHE Policy, we tend to obey the directions and definitions delineated on the employment of Animals and Alternatives in Education and Training (Martinsen and Jukes, 2007). According to the Policy of the Jukes, 2014, the beginning of every animal and the cause for loss of life or euthanasia (mercy killing) were thought of in order that the animal cadavers have been "ethically sourced" or from "appropriate different resources".

Most of the animals (dog and cat) that have significant non-recoverable injury or terminal sickness will be euthanized in the clinic. They enclosed stray animals, operating animals and patients from the faculty hospital's surgical clinic who had been given with the owner's permission. The right choice of potential individual animal cadavers and specimens ensures that specimens are appropriate to be used in practical classes and prevents losing time, attempt,

* Corresponding author: osama.ahmed@fvtm.bu.edu.eg

cash preserving and bad specimens. Non-castrated animals are recommended than castrated animals as castrated animals are generally overweight.

Preservation of Fish and mice for teaching and training the students while studying the ichthyology and lab animals' anatomy respectively.

Animals that have died from extreme infectious illnesses or septicemia are prohibited for maintenance to symbolize healthy structures; but uncommon pathological samples may be maintained. Intravenous injection of the animals with xylazine as a sedation and thiopental sodium as an anesthetic solution to ensure humane euthanasia. After completing surgical anesthesia, dissect the common carotid artery that was located dorsolateral to the trachea. The Heparin was injected into the common carotid artery with a dose of 1-2 ampoules per 1 liter of saline. The process of heparin injection must be carried out in all cases of execution in all methods of preservation, especially if it was injected with colored latex in order to facilitate the process of its passage to all parts of the tissues. After injection, cut the common carotid artery and allowed the animal to bleed until death.

2.2. Modified form of the Elnady Technique's steps is as follows:

2.2.1. Formalin fixation:

Fixation of tissue is carried out in a way just like plastination. Some issues will be emphasized that have been discussed in detail in earlier papers regarding plastination (Ostrom, 1987). The procedure used to fix tissue with formalin is determined by the target specimen. The most popular approach is to euthanize the animal while it is bleeding, followed by canalization and injection of ten percent formalin into the common carotid artery. The embalming fluid is added either through a syringe with hand stress in case of small animals and fish or via gravity-feed from a container held 0.9 - 1.8 m above the specimen in case of large animals, depending on the pressure wanted. Generally, when there's resistance for injection of the embalming solution, this means that enough solution has been injected. As an example, a dog needs two to three liters of the embalming solution even as approximately 1 liter is needed for a cat.

Then leave the cadavers inside the morgue at ambient temperature for about ten days for the tissues to turn out to be completely saturated with formalin. After injection, some changes happened to cadavers such as particularly bloated tissues, erected ears, stiff limbs and stiff, pale and whitish tongue. Then, dissect the animal body to be ready for future practical lessons. The samples may be small animals, organs or tissues that demonstrate the structure efficiently for practical anatomy or surgery classes.

Organs taken from dead animals are cannulated within the main arteries and injected with 20% formalin, and then submerged in a 5% formalin bath for approximately three weeks. The lower concentration of formalin bath rather than the higher concentration permits the formalin to reach the tissues of superficial and deep structures.

2.2.2. Injection of colored Latex, dissection of muscle and drilling of bone:

It is better to inject latex into the animal immediately after killing before injecting it with formalin, because formalin will cause the blood capillaries to shrink. To avoid this, it is

preferable to inject it while it is in a fresh state, the injection of Colored latex into arteries or cavities enhanced the visibility of features in specimens once cannulation is viable as shown in Figure 1C.

For whole animals as dog and cat cadavers, incision and reflection of the skin and superficial fascia, and then split the deep fascia to permit the muscles to break free one another partly or fully as shown in Figure 1E. This guarantees that the acetone and glycerin employed in the subsequent dehydration and impregnation processes will penetrate the whole specimen. It's additionally essential to work on bones, tiny pores are digging into the long bones in less visible areas and also holes in the thorax to improve defatting and avoid greasy specimens as illustrated in Figure 1J and K.

At this level, hollow organs as the stomach and gut need to be cleaned of aliment by washing under running water. The heart is incised to ensure there are no blood clots as shown in figure 1K. The Midsagittal section of the body of the dog and cat is performed to show the viscera in situ as shown in Figure 2G.

2.2.3. Acetone for dehydration:

The dehydration process is carried out fully at ambient temperature. After washing the specimen with water, it is submerged in an acetone bath with a 100% concentration for one week. Following that, measured the acetone concentration by a hydrometer, and the specimen is moved to a new pure acetone bath and kept for one more week. The specimens are considered dehydrated once the concentration of acetone stays consistent at 98-99% while measured at irregular intervals.

2.2.4. Glycerin for impregnation:

After finishing the dehydration step, the specimens are lightly squeezed by hand and let to empty of acetone via a strainer. They're then completely submerged in a glycerin bathtub for 1-2 weeks according to the sort and size of the organs. Small organs, hollow organs and skinny walled tissue of any size take approximately one week for the whole impregnation.

2.2.5. Cornstarch for curing:

The specimens are removed from the glycerin, let to empty, after which well wiped clean out using tissue paper. They've then positioned in cloth bags two or three times the dimensions of the samples and cornstarch powder is introduced. Then firmly ligated the bags and rubbed with cornstarch powder from outside. Alternatively, tiny samples can be submerged in cornstarch powder containers for 1-3 days. Within this period, it is advised that you switch and rub-down the samples within the luggage on a regular basis. Cornstarch powder that has been soaked with glycerin tends to clump and need to get replaced.

Eventually, the specimens are carefully removed from the bags after approximately a week, when the starch no longer clumps. Cornstarch residue on the samples should be cleaned with a gentle brush or blown away with air. If the specimen continues to ooze glycerin, it's came back to the fabric bag and therefore the procedure is continued till the starch now not clumps. If essential, the samples may be alternatively rubbed immediately with cornstarch and kept for one or over weeks within the outdoors lying on flat pasteboard to assist soak up glycerin. The completed

samples are saved in a clean place such as an anatomy museum.

3. RESULTS

A wide range of samples was created, each representing a distinct bodily system from various animal species at a different time (recently preserved and preserved from 4 years ago). We used acetone at room temperature to dehydrate the specimens, and they show little shrinkage and nice color. The produced samples are lifelike, robust, soft and flexible, in contrast to traditional plastination. They are cleaned and do not have an offensive odor.

The specimens are divided into the following categories:

Viscera in situ:

The thoracic viscera including the heart, lungs pleura and pericardium; abdominal viscera were including the diaphragm, liver, spleen, stomach, kidneys and adrenals as well as the serous membranes that surrounded them and the peritoneum and pelvic viscera including urinary bladder, descending colon of dog, cat and mice are shown in situ via holes in thorax and abdomen as illustrated in Figures 1, 2 and 3 respectively. The visceral neurovascular supply is obviously visible, especially if injected with colored latex. The Midsagittal section of a cat was developed to demonstrate the thoracic, abdominal and pelvic viscera in situ as described in Figure 2G.

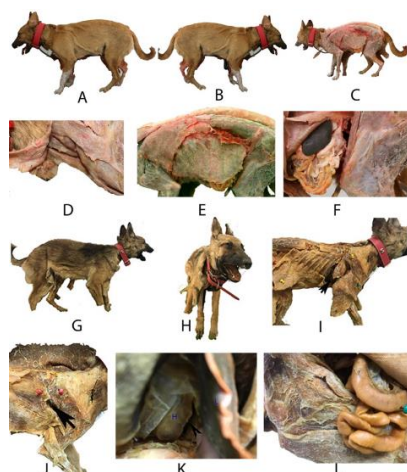


Figure 1 Dogs preserved with the modified form of the Elnady technique.

(A –F): a dog cadaver freshly preserved and (G-L): a dog cadaver preserved from 4 years ago.

(A) (B) Full dog cadaver in standing position; (C) dissected dog cadaver in standing position and injected with red-colored Latex; (D) dissected of neck of a dog; (E) trunk of a dog with skin reflected; (F) Viscera in situ of a dog ; (G) Full dog cadaver in standing position(side view) ; (H) Full dog cadaver in standing position(front view); (I) Full dog cadaver with skin reflected and arrow referred to hole in thorax; (J) a dissected dog with skin reflected and arrow referred to a hole in the thorax; (K) longitudinal section through the heart; ensuring there are no blood clots (H: heart, L: lung); (L) Viscera in situ of a dog.

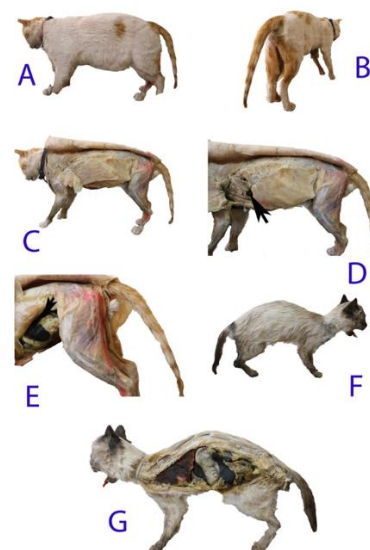


Figure 2 Cats preserved with the modified form of the Elnady technique.

(A) Full cat cadaver in standing position(side view); (B) Full cat cadaver in standing position(hind view) (C) dissected cat cadaver in standing position and injected with red-colored Latex; (D) a dissected cat with skin reflected and arrow referred to a hole in the thorax; (E) The hind half of cat and arrow showing the viscera in situ ; (F) Full cat cadaver in standing position(side view) preserved from 4 years ago;(G) Midsagittal section of the body of a cat showing the viscera in situ.

Hollow viscera:

The heart, lung, liver and stomach of the donkey and one buffalo calf are examples of preserved viscera. The longitudinal section of the kidney of sheep and horse was also created. The anatomical features internally and externally are obvious and can be dissected later if needed. The uterus with ovaries of a cow was also preserved and showing the pathological condition that is the cystic ovary as shown in Figure 4.

Musculoskeletal specimens:

Dissection of the dog and cat were performed to show muscles of the thoracic limb, neck, hind limb and trunk with their covering with superficial and deep fascia as described in Figures 1 and 2. The blood vessels, nerves and other anatomical structures were available and should be dissected if required later.

Mice and fish specimen:

The mice and fish were preserved for teaching and training the students while studying the ichthyology and lab animals' anatomy respectively as described in Figure 3. The abdominal organs were also preserved *in situ* in abdominal incision of mice in lateral recumbency position as illustrated in Figure 3B. *Haemulon maculicauda*, *Pagrus pagrus* and *Dicentrarchus punctatus* fishes were preserved by modified form of the Elnady technique as examples of fishes that were required for studying ichthyology as illustrated in Figures 3E, F and G respectively.




Figure 3 A mice and fish preserved with the modified form of the Elnady technique.

(A) a mouse in standing position (side view); (B) a mouse in lateral recumbency position (abdomen incision showing the viscera in situ); (C) a mouse in standing position (front view); (D) a mouse in lateral recumbency position; (E) *Haemulon maculicauda* Fish; (F) *Pagrus pagrus* fish; (G) *Dicentrarchus punctatus* fish.

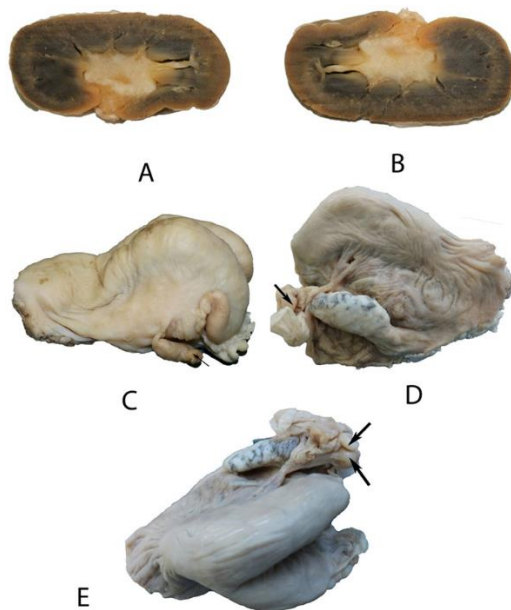


Figure 4 Images of a kidney and female genital tract of cow preserved with modified form of the Elnady technique.

(A) and (B) longitudinal section via the kidney of a sheep; (C- E) female genital tract of cow and arrow showed the cystic ovary.

4. DISCUSSION

The main chemicals used in plastination other than this work and Elnady techniques are patented and often unavailable locally. Another issue is the high cost of establishing plastination units especially for the creation of medium and large-sized specimens (Baptista et al., 1992),

in otherwise; this work and Elnady technique are used cheaply, well known, reasonable and locally accessible.

In the present study, the Heparin was injected into the common carotid artery for complete bleeding. It has been confirmed that there are no blood clots when incised the heart during preparation. While Elnady, 2016 excluded this step.

Klaus and Dubravka, 1988 and Henry, 1998 used the acetone for dehydration process at -25°C while Zheng et al., 1998; Elnady, 2016 and this work used the acetone at room temperature. Furthermore, using it at ambient temperature minimizes the danger of explosion and removes the need for explosion-proof freezers, resulting in reduced total costs.

After dehydration, the major process is impregnation. Piombino-Mascali et al., 2009 reported that glycerin has been added to several embalming fluid formulations, including the one used to preserve Rosalia Lombardo. While An et al., 2012 and Li et al., 2012 employed Glycerin to create translucent or semitransparent specimens. Furthermore, Carvalho et al., 2013; Gigeck et al., 2009; Silva et al., 2008 and Cury et al., 2013 utilized glycerin to preserve isolated organs.

The present study and Elnady, 2016 used Glycerin, because it has four key qualities that aid in tissue preservation: it is nontoxic, has plasticizing and hygroscopic properties, and has a strong penetrating power, which removes the need for vacuum pumps. While Nashed et al., 2003 stated that Glycerol is used as a plasticizer in several biodegradable packaging materials to reduce brittleness and produce the required flexibility.

Curing is the last procedure. Plastination employs heat, UV light, and gas curing using silicone-6 (S-6), whereas the present work and Elnady, 2016 used cloth bags filled with cornstarch. The surfaces of the tissues become too dry and lose their stickiness due to the adherence of cornstarch with glycerin.

The preserved specimens are realistic, long-lasting, odorless, dry, flexible and soft. They also exhibit natural colors as unpreserved specimens. When stored properly, they will survive for a long time without degradation. Those mentioned above are in a standard condition more than one year and 4 years after producing that is preserved by Elnady and modified form of the Elnady techniques respectively.

The preserved genital tract of the cow by modified form of the Elnady technique that demonstrated the pathological conditions as cystic ovary gave a great chance for application in clinical skills and surgical training. This is similar to findings with Elnady et al. (2016) that who added that because the microorganisms were subjected to formalin and acetone dehydration throughout the conservation procedure, the unlike pathological samples can be kept up without hazard of disease.

The development of the longitudinal section of a kidney preserved by this work can aid in the comprehension of current imaging modalities like ultrasound. This is agreeing with Elnady, 2016; Latorre et al., 1998, 2001; Lawrence and Gunther, 1988.

In contrast to the Elnady technique, the present study enables to preserve the whole animals as dog and cat for long periods without degradation or rotting. In this work, it is confirmed from the durability of preserved specimens via checking of specimens after over 4 years we found that there are no deteriorations.

5. CONCLUSION

The modified form of the Elnady technique for tissues preservation differs from the Elnady technique in that heparin is injected after humane euthanasia for complete bleeding. All steps proceed at ambient temperature with locally accessible chemicals including formalin, acetone, glycerin and cornstarch for fixation, dehydration, impregnation and curing respectively. The preserved specimens are realistic, long-lasting, odorless, soft, flexible and dry. They are of significant benefits to students and teachers of the Faculty of Veterinary Medicine at Benha University in understanding and studying anatomy without exposure to the harmful effects of formalin.

6. REFERENCES

- An, X., Yue, B., Lee, J. H., Chenghe Lin, C., and Han, S. H., 2012. Arterial anatomy of the gracilis muscle as determined by latex injection and glycerin transparency. *Clin Anat* 25, 231-234. <http://dx.doi.org/10.1002/ca.21217>
- Baptista, C. A., Bellm, P., Plagge, M. S., and Valigosky, M., 1992. The use of explosion proof freezers in plastination: Are they really necessary? *J IntSoc Plastination* 6, 34-37.
- Bickley HC., 1984. Plastination: A new technique for anatomic pathology and forensic science. *Pathol. Update Series*. 2(16):2-8.
- Brenner, E. 2014. Human body preservation – old and new techniques. *J Anat* 224, 316-344. <http://dx.doi.org/10.1111/joa.12160>
- Carvalho, Y. K., Zavarize, K. C., Medeiros, L. d. S., and Bombonato, P., 2013. Evaluation of the glycerin from biodiesel production in the preservation of anatomical parts. *Pesq Vet Bras* 33, 115-118. <http://dx.doi.org/10.1590/S0100-736X2013000100021>
- Cury, F. S., Censoni, J. B. and Ambrósio, C. E. 2013. Técnicas anatômicas no ensino da prática de anatomia animal. *Pesq Vet Bras* 33, 688-696. <http://dx.doi.org/10.1590/S0100-736X2013000500022>
- Elnady, F. A., Sheta, E., Khalifa, A. K., Rizk, H., 2015. Training of upper respiratory endoscopy in the horse using preserved head and neck. *ALTEX* 32, 384-387. <http://dx.doi.org/10.14573/altex.1505111>
- Elnady, F. A. 2016. The Elnady Technique: An Innovative, new method for tissue preservation. *ALTEX* 33 (3), 237-242 .
- Gigek, T., Oliveira, J. E. M., Neto, A. C. A., Carvalho, W. L., Pereira, F. V., and Almeida, A. H., 2009. Estudo Analítico da Técnica de Gliceração Empregada para Conservação de Peças Anatômicas de Bovinos. *Anais V Simpósio de Ciências da UnespDracena, SP*. 1-3.
- Jukes, N., 2014. Ethical animal use in education and training: From clinical rotations to ethically sourced cadavers. *ATLA* 42, 9-12.
- Henry, R. W., 1998. Principles of plastination – dehydration of specimens. *J IntSoc Plastination* 10, 27-30.
- Kamath VG, Shetty RK, Asif M, Ramakrishna A., 2013. A Comparative Study of Tracheobronchial Pattern Using Luminal Plastination. *Int J Anat Res*. 1(3):161-64.
- Klaus, T. and Dubravka, I. 1988. Dehydration of macroscopic specimens by freeze substitution in acetone. *J IntSoc Plastination* 2, 2-12.
- Latorre, R., Vazquez, J., Gil, F., Ramirez, G. O., López O, Ayala, M. D., Ramírez, G., Vázquez, J.M., Arencibia, A., and Henry, R.W., 1998. Macroscopic interpretation of horse head sectional anatomy using plastinated S-10 sections. *J IntSoc Plastination* 13, 39.
- Latorre, R., Vazquez, J. M., Gil, F. Ramirez, G. O., Lopez-Albors, M., Orenes, F., Martinez-Gomariz and Arenciba, A., 2001. Teaching anatomy of the distal equine thoracic limb with plastinated slices. *IntSoc Plastination* 16, 23-30.
- Lawrence, M. and von Gunther, H. 1988. The diagnostic imaging characteristics of plastinated anatomical specimens. *J Int Soc Plastination* 2, 24-38.
- Li, J., Shi, S., Zhang, X. Ni, S., Wang, Y., Curcio, C. A., Chen, W., 2012. Comparison of different methods of glycerol preservation for deep anterior lamellar keratoplasty eligible corneas. *Invest Ophthalmol Vis Sci* 53, 5675-5685. <http://dx.doi.org/10.1167/iov.12-9936>
- Martinsen, S. and Jukes, N., 2008. From policy to practice: Illustrating the viability of full replacement. *AATEX* 14, Spec. Issue, 249-252.
- Nashed, G., Rutgers, R. P. G. and Sopade, P. A., 2003. The plasticisation effect of glycerol and water on the gelatinisation of wheat starch. *Starch-Starke* 55, 131-137. <http://dx.doi.org/10.1002/star.200390027>
- Ostrom, K., 1987. Fixation of tissue for plastination: General principles. *J Int Soc Plastination* 1, 3-11.
- Pashaei S., 2010. A brief review on the history, methods and applications of plastination. *Int. J. Morphol.* 28(4):1075-1079
- Piombino-Mascali, D., Aufderheide, A. C., Johnson-Williams, M., and Zink, A. R., 2009. The Salafa method rediscovered. *Virchows Arch* 454, 355-357 .
- Ravi, S.B., and Bhatt, V. M., 2011. Plastination: A novel, innovative teaching adjunct in oral pathology. *Journal Oral Maxillofacial Pathology*. 15(2):133-137.
- Silva, E. M., Dias, G., and Tavares, M., 2008. Study of glycerination method used for conservation of anatomic parts – Experience of Anatomy discipline of the Morphology Department / UniFOA. *Cadernos UniFOA, Volta Redonda, RJ, Special Edition Graduate* 01. 66-69.
- Srisuwatanasagul K, Srisuwatanasagul S, Adirekthaworn A, Darawiroj D. 2010. Comparative Study between Using Acetone and Absolute Alcohol for Dehydration in Plastination Procedure. *Thai J. Vet. Med.* 40(4):437-440
- vonHagens G., 1979. Impregnation of soft biological specimens with thermosetting resins and elastomers. *Anat Rec*. 194:247-256.
- Zheng, T., Liu, J. and Zhu, K., 1998. Plastination at room temperature. *J IntSoc Plastination* 13, 21.